



PATIENT

Ruby Warshawsky

SPECIES

Feline

BREED

British SH

SEX

Female Spayed

AGE

9 years

WEIGHT

10.3lbs

INTERPRETED BY

Maggie Machen
Lamy, DVM, DACVIM
(Cardiology)

HOSPITAL NAME

Cat Hospital at
Towson

REFERRING VET

Dr. Brunt

INVOICE

21334

DATE

10/4/21

PRESENTING CLINICAL SIGNS

History: New client/patient presenting for vaccine update. Gallop rhythm on PE with normal rate. BP 140mmHG, normal cardiac blood marker.

-Pertinent abnormal PE/Chem/CBC/UA Results: Possibly stage 1 CKD, no other concerns.

-Blood pressure: 140mmHg,

-STAT: Not requested.

ECHOCARDIOGRAM FINDINGS

2D, m-mode, color flow and doppler imaging is available. The left ventricular wall is normal to slightly decreased in dimension. There is a diffusely hyperechoic endocardium consistent with fibrosis. False tendons. The endocardium also appears remodeled. The left atrium is normal in size. The right atrium is normal in size. The right ventricle appears normal. The mitral valve is normal in structure and mobility. Blood flow through the LVOT and RVOT is normal in velocity. No obvious valve leaks. Normal aortic and pulmonic valves. No evidence of cardiac tumors or metastatic lesions on this scan. No effusions seen.

CARDIAC CHART

FELINE CARDIAC PARAMETERS	BODY WEIGHT (kg)	HR (BPM)	IVSd (cm) (Moise, Pipers)	LVIDd (cm) (Moise, Pipers)	LWVd (cm) (Moise, Pipers)	FS (%)	EF (%)
NORMAL PARAMETER	-----	150-240	3.5-0.55	<2 (mean 1.5)	3.5-0.55	35-67	80-100
PATIENT	4.7	234	0.36	1.23	0.36	67	95
FELINE CARDIAC PARAMETERS	LA/AO (Boon)	LA/AO HEART BASE (Swe) (Abbott)	LA 2D short axis Base view (cm) (Abbott)		LVOT VEL (m/s)	RVOT VEL (m/s)	E max (m/s)
NORMAL	<1.5	<1.3	<1.2		<1.6	<1.3	<0.9
PATIENT	NM	1.3	1.2		0.6	0.82	NM
Adapted from June Boon, Veterinary Echocardiography, 1998 Abbott J & MacLean H JVIM 2006;20: 111-119, Moise et al. Am J Vet Res 47:1476, 1986. Pipers et al. Am J Vet Res 40:882, 1979.							

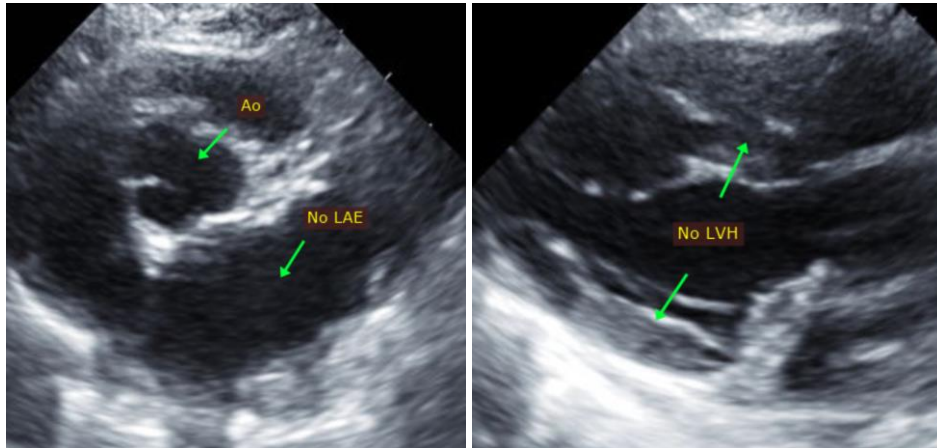
INTERPRETATION OF THE FINDINGS & FURTHER RECOMMENDATIONS

Overtly normal cardiac structure and function. There is subjectively more remodeling and fibrosis of the left ventricular wall than is suspected in a 9-year-old cat and follow up is advised to determine significance. The overall function at this time appears normal with a normal left atrial dimension. Monitor for development of respiratory signs or evidence of a blood clot event (paralysis, neurologic change, etc.).

Given these findings, no medications are indicated. Anesthetic risk is considered mild if needed, and there is no contraindication to proceeding as you would with any geriatric cat. However, with this degree of remodeling and diastolic stiffening there is an elevated risk for fluid overload and judicious IV fluid use is recommended. Monitor HR/ECG both intra-op and post-op.

Recommend recheck echocardiogram in 1 year to assess for progression/development of silent cardiomyopathy.

IMAGES



The information and recommendations provided are based on the images presented by the referring veterinarian. No evaluation can be communicated regarding pathology that was not visible in the image/video clips provided.

Thank you for this referral. This report was generated using transcription software, and minor dictation errors may be present. If the clinical or image interpretation does not parallel your findings or if I can be of any further assistance, please contact me.

Maggie Machen Lamy, DVM
Diplomate of the American College of Veterinary Internal Medicine (Cardiology)
Email: info@sonopath.com